



**PHILIPS**

Image guided therapy

Lung suite

# Image guided Video Assisted Thoracoscopic Surgery (iVATS)

**assisted by cone beam CT and 3D live needle guidance**

## Patient history

This is a 57 years old male presenting with an increasing right upper lobe lung nodule. He was a current smoker (2 packs per day) and had a smoking history of over 100 pack years. Over 2 years of lung screening, his nodule grew from 2 to 6 mm with a suspicion of an early lung cancer in a high risk person meeting the National Comprehensive Cancer Network (NCCN) screening criteria. His lung function was significantly diminished and his performance status was limited. He asked for complete excision of the nodule but he was not a candidate for a formal lobectomy due to limited lung function and performance status.

His lesion was deep in the lung parenchyma and therefore not palpable and accessible using a classical video assisted thoracoscopic surgery (VATS) approach. He was offered a limited lung resection via image guided VATS (iVATS) using intra-operative cone beam CT.

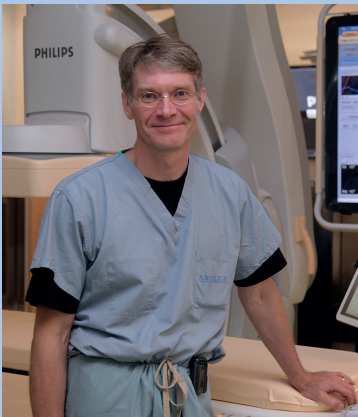## Procedure

The patient underwent the iVATS procedure in a hybrid operating room (OR). Subsequent to double lumen intubation, the patient was placed in the lateral decubitus position. The ceiling mounted C-arm system (Allura Clarity FD20 Flexmove, Philips) was positioned on the left side of the patient, centering the field of view of the detector to include the region of interest. A cone beam CT scan was acquired using an 8-second roll protocol (XperCT, Philips), while temporarily suspending mechanical ventilation. Using the cone beam CT data, the 6mm lesion was segmented by the physician and fiducial needle paths were further planned defining the target point and the entry point using commercially available software (Lung suite, Philips). The software enables verification and feasibility of the planned needle path avoiding any vital structures. The field was prepped and draped and fiducial markers were inserted beyond the lesion to increase the resection

margin. The percutaneous marking procedure was guided using automatically selected fluoroscopic views (3D entry point view and progress view) of the planned needle path augmented by the 3D segmented lesion overlay (Lung Suite, Philips). Geometric correspondence of live fluoroscopy and 3D overlay was automatically maintained throughout the procedure while manipulating C-arm angulation, table position and image-zoom settings.

A standard 3-port VATS approach was used to access the chest. Under real-time fluoroscopy, the fiducials were identified and a wedge resection was outlined with tissue clamps and/or marking pens. The ceiling mounted Flexmove

C-arm system was then moved to its parking position, providing ample space for surgery. Further, the wedge resection was performed using an endoscopic stapler device and the specimen was retrieved in a bag. The nodule was identified and frozen sections were sent for tissue diagnosis. Final pathologic examination confirmed that the lesion was an early lung cancer. The patient underwent a systematic lymph node dissection in the same setting and was staged as an IA1 (T1a, N0, M0) adenocarcinoma. This case was presented at the multidisciplinary tumor board and he has entered routine radiologic follow-up.



## Dr. Carsten Schroeder

is a thoracic surgical oncologist at the Georgia Cancer Center and Medical College of Georgia at Augusta University Health, working with Philips through a unique long-term partnership model that allows collaboration in creating clinical solutions, Augusta University Health opened its hybrid operating room in May 2017.

## Conclusion

Using the hybrid OR with cone beam CT, navigational bronchoscopy, percutaneous biopsy, fiducial placement, and iVATS can be combined into a single-stage, single-provider procedure allowing for diagnosis and treatment in one setting. Representing a paradigm shift in thoracic surgery, the hybrid OR provides one stop workflow eliminating multiple clinical visits for improved patient experience and care. This streamlined approach not only avoids the upstaging and worse prognosis associated with delayed treatment but is also a cost-effective paradigm for the institution.

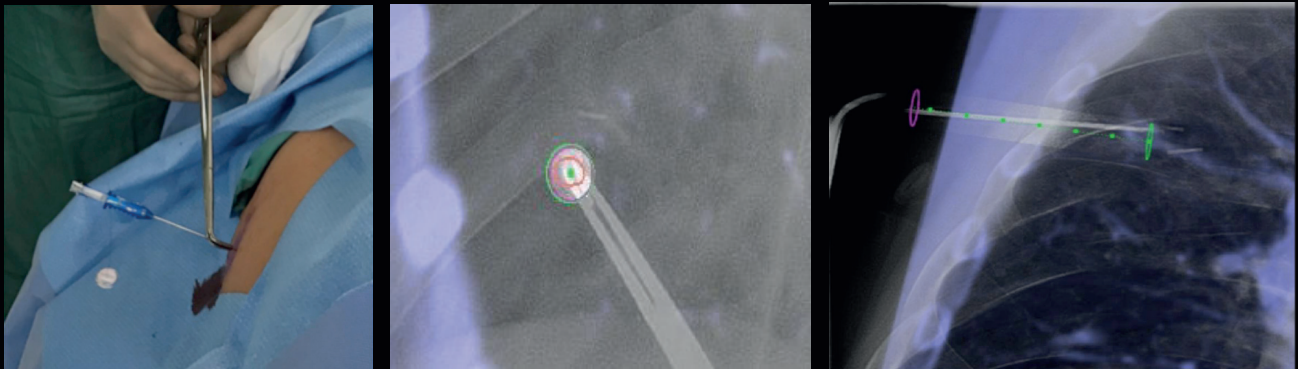


Figure 1: Fiducial marker placement. 2D live fluoroscopic overlay with 3D needle path and cone beam CT volume showing Entry Point view (middle) used to align the needle and the target nodule, and Progress view (right) used to advance the needle towards the target nodule. The fiducial markers are visible on fluoroscopy and positioned beyond the nodule.

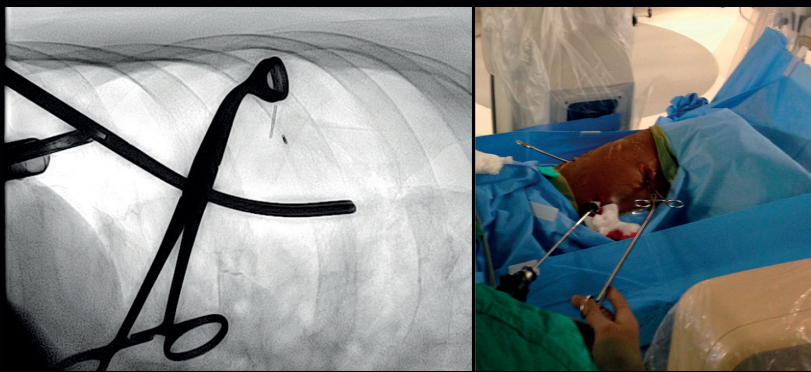


Figure 2: The VATS wedge resection was performed by following the fiducial marker string to the lesion and confirmed with on-table fluoroscopy to ensure that the non-palpable lesion was in the wedge resection specimen.

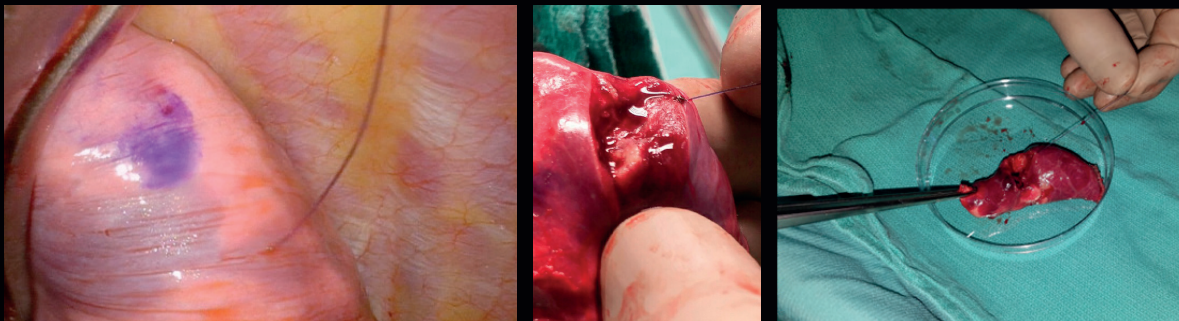

Figure 3: The fiducial marker string can be seen in the endoscopic view (left) and then the T-fastener marker is also shown within the specimen (middle, right).



Results from case studies are not predictive of results in other cases.  
Results in other cases may vary.

© 2019 Koninklijke Philips N.V. All rights reserved. Specifications are subject to change without notice. Trademarks are the property of Koninklijke Philips N.V. or their respective owners.

4522 991 41101 \* JAN 2019

**How to reach us**  
Please visit [www.philips.com](http://www.philips.com)  
[healthcare@philips.com](mailto:healthcare@philips.com)  
[www.philips.com/lungsuite](http://www.philips.com/lungsuite)