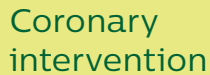


The Philips logo is displayed in a bold, blue, sans-serif font within a white rectangular box.The ELCA logo is displayed in a bold, white, sans-serif font within a green rectangular box.The text 'Coronary laser atherectomy catheter' is displayed in a white, sans-serif font within a light green rectangular box.The text 'Coronary intervention' is displayed in a white, sans-serif font within a yellow rectangular box.A background image of a surgeon in a blue scrub suit, wearing a blue surgical cap and a white face mask, looking down intently in an operating room. The lighting is focused on the surgeon, with a blurred background showing other medical equipment and staff.

Bilodeau data sheet

Novel use of a high-energy excimer laser catheter for calcified and complex coronary artery lesions

Purpose

To evaluate the safety and efficacy of the 0.9mm X-80 excimer laser with increased laser parameters in patients with calcified and/or balloon resistant lesions.

Methods

- Prospective multicenter study @ 4 sites
- 100 calcified and/or balloon resistant lesions
- Inclusion criteria
 - >80% stenosis (severely stenotic) with:
 - Angiographic evidence of calcium
 - Or a CTO with angiographic evidence of TIMI 0 flow without acute events, unstable angina or CK rise 3 months prior to procedure
 - Or lesion traversable by a guide wire and uncrossable by a 1.5mm balloon
- Safety and efficacy data compared from 2 groups
 - Standard laser therapy (SLT)
 - 60 fluence and 40 hertz
 - Increased laser therapy (ILT)
 - 60 fluence and 80 hertz
 - 80 fluence and 80 hertz
- Initial treatment was SLT followed by PTCA/stenting
- If laser failed to cross, ILT was initiated in a stepwise manner – 60/80 then 80/80
- 12 laser trains were attempted before failure declared - 3 trains at each setting (60/40, 60/80 and 80/80). 80/80 was attempted once more a after recalibration
- Laser technical success was defined as the laser crossing the entire lesion
- Procedural success was defined as < 50% residual stenosis after laser and adjunctive therapy

Results

- **92% total (SLT+ILT) laser technical success**
- **93% total procedural success**
- **66 lesions crossed successfully via SLT**
- **29 lesions required ILT**
 - 12 @ 60/80
 - 17 @ 80/80
- **Lesion characteristics**
 - 80% calcification
 - 35% balloon failure
 - 28% CTO
- **ACC/AHA lesion classification**
 - Type A – 0%
 - Type B1 – 8%
 - Type B2 – 61%
 - Type C – 31%
- **Complications (n95)**
 - Laser related – 5
 - Dissection – 5
 - Perforation – 0
 - Spasm – 0
 - No reflow/embolization – 0
 - Thrombus formation – 0
 - Acute closure – 0
- **Laser complications did not seem to be related to increased laser parameters**
- **8 lesions were not able to be crossed completely by the laser**
 - 4 of these lesions were able to be successfully treated after the laser attempts with PTCA/stenting – raising the possibility that the laser had changed the compliance of the lesion, allowing for definitive treatment
- **Higher laser energy levels seem to be safe and effective for management of calcified and nondilatable lesions**

Important safety information

ELCA X-80 coronary laser ablation catheter

Indications

The X-80 laser catheters are intended for use as a stand-alone modality or in conjunction with percutaneous transluminal coronary balloon angioplasty (PTCA) in patients who are acceptable candidates for coronary artery bypass graft (CABG) surgery. The following Indications for use, contraindications and warnings have been established through multicenter clinical trials. The Philips CVX-300 excimer laser system and the multifiber laser catheter models are safe and effective for the following indications:

- Occluded saphenous vein bypass grafts
- Ostial lesions
- Long lesions - (greater than 20mm in length)
- Moderately calcified stenoses.
- Total occlusions traversable by a guidewire.
- Lesions which previously failed balloon angioplasty - This includes those lesions that were treated unsuccessfully by PTCA. Lesions that have undergone a complicated PTCA procedure are not included in this category. These lesions must be traversable by a guidewire and composed of atherosclerotic plaque and/or calcified material. The lesions should be well defined by angiography.

Contraindications

- Patient has acute thrombosis.
- Lesion is in an unprotected left main artery.
- Patient has experienced an acute myocardial infarction.
- Patient has ejection fraction of less than 30%.
- Lesion is beyond acute bends or is in a location within the coronary anatomy where the catheter cannot traverse.
- Guidewire cannot be passed through the lesion.
- Lesion is located within a bifurcation.
- Patient is not an acceptable candidate for bypass graft surgery.

Warnings

Federal (USA) law restricts this device to sale by or on the order of a physician with appropriate training. A clinical investigation of the Philips CVX-300 excimer laser system did not demonstrate safety and effectiveness in lesions amenable to routine PTCA or those lesions not mentioned in the Indications for Use, above. The effect of adjunctive balloon angioplasty on restenosis, as opposed to laser alone, has not been studied. The use of the CVX-300 excimer laser system is restricted to physicians who are trained in the use of the product.

Precautions

This device has been sterilized using ethylene oxide and is supplied STERILE. The device is designated and intended for SINGLE USE ONLY and must not be resterilized and/or reused. Store in a cool, dry place. Protect from direct sunlight and high temperatures (greater than 60°C or 140°F). During the procedure, appropriate anticoagulant and coronary vasodilator therapy must be provided to the patient. Anticoagulant therapy should be administered per the institution's PTCA protocol for a period of time to be determined by the physician after the procedure. Percutaneous excimer laser coronary atherectomy (ELCA) should be performed only at hospitals where emergency coronary bypass graft surgery can be immediately performed in the event of a potentially injurious or life-threatening complication. The results of clinical investigation indicated that patients with the following conditions are at a higher risk for experiencing acute complications:

- Patients with diabetes.
- Patients with a history of smoking.
- Lesions with tortuous vessels.

See complete IFU for more information before attempting use of ELCA X-80.

